

SUBDURAL BLOCK AND THE ANAESTHETIST

Anaesthesia and Intensive Care, 2010, Vol 38, No. 1

D Agarwal, M Mohta, A Tyagi, AK Sethi

Department of Anaesthesiology and Critical Care, University College of Medical Sciences and Guru Teg Bahadur Hospital, Delhi, India

SUMMARY

There are a number of case reports describing accidental subdural block during the performance of subarachnoid or epidural anaesthesia. However, it appears that subdural drug deposition remains a poorly understood complication of neuraxial anaesthesia. The clinical presentation may often be attributed to other causes. Subdural injection of local anaesthetic can present as high sensory block, sometimes even involving the cranial nerves due to extension of the subdural space into the cranium. The block is disproportionate to the amount of drug injected, often with sparing of sympathetic and motor fibres. On the other hand, the subdural deposition can also lead to failure of the intended block. The variable presentation can be explained by the anatomy of this space. High suspicion in the presence of predisposing factors and early detection could prevent further complications. This review aims at increasing awareness amongst anaesthetists about inadvertent subdural block. It reviews the relevant anatomy, incidence, predisposing factors, presentation, diagnosis and management of unintentional subdural block during the performance of neuraxial anaesthesia.

Central neuraxial blockade is a commonly performed anaesthetic technique¹. While generally being a very reliable technique, occasionally an unexpectedly high or low level of block is achieved. This could potentially be secondary to the deposition of local anaesthetic in a meningeal plane other than that desired. One such plane is the subdural space, which lies between the dura and arachnoid mater. Unintentional injection of local anaesthetic into the subdural space has been seen to result in both a wide dermatomal spread²⁻⁷ as well as an inadequate block^{8,9}.

Though there are numerous published case reports of unintentional subdural blockade, it still remains a less well recognised complication of central neuraxial blockade. It may be mistaken for an inadvertent subarachnoid injection, migration of the epidural catheter tip or an inadequate, unilateral or patchy epidural block. A greater awareness of the potential for a subdural injection is important, as it requires strict vigilance and timely intervention to avoid potentially critical complications and an unexpected failure of the technique. Further injection into the subdural space may potentially cause neurological damage³. The aim of this paper is to review clinical aspects of subdural block. To our knowledge, no previous detailed reviews have been published.

METHODS

A search from the National Library of Medicine's PubMed database was conducted up to April 2009, using the following key words: subdural, epidural, anaesthesia, regional block, complications. Sixty-five relevant citations available in English were retrieved out of 189 search results. These included 45 case reports, 13 letters to editors, two editorials and five clinical studies. Out of these five clinical studies, one was a comparative study of reported cases of subdural block and two were radiological studies. The remaining two studied epidural blocks and their complications. Reference lists of relevant articles were also scrutinised.

ANATOMY

The subdural space is a narrow potential space between the arachnoid mater and the dura mater containing a minute quantity of serous fluid¹⁰. It extends into the cranial cavity throughout the distribution of the meninges, covering all neural structures¹⁰. The space ends distally at the lower border of the second sacral vertebra, where the filum terminale becomes invested closely by the dura mater¹¹.

The spinal subdural space has greater potential capacity dorsally and laterally¹². It is widest in the cervical region and most narrow in the lumbar region. The usual sparing of sympathetic and motor functions associated with a subdural block is due to the anatomy of this space¹³. The space is known to extend laterally like a cuff over the exiting dorsal nerve roots. The arachnoid mater is fixed proximal to the dorsal ganglia and the dura mater distal to it, thereby also extending the subdural space over the dorsal root ganglia¹⁴ (Figure 1A). The dura and arachnoid mater are attached together on the ventral root and hence the potential space is much smaller

ventrally. Subdural injections thus usually pool in the posterior segment, sparing the anterior nerve roots that carry the sympathetic and motor nerve fibres¹⁵.

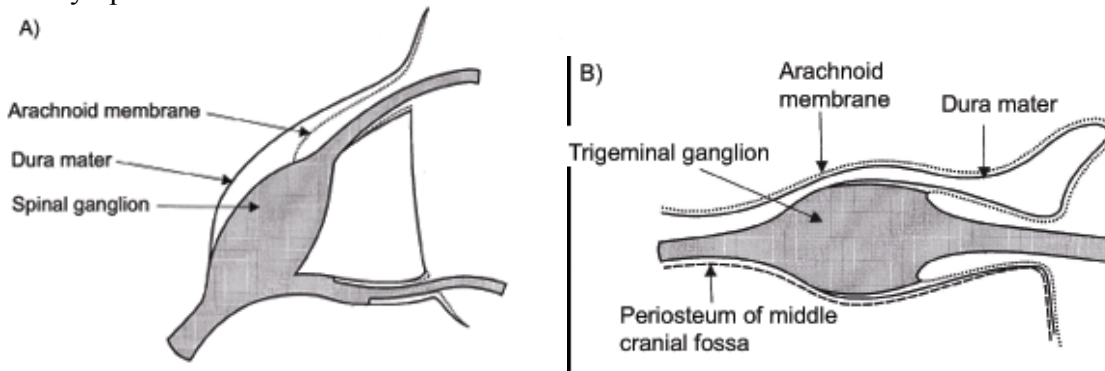


Figure 1: Diagram showing extension of subdural space over A) dorsal root ganglion and B) trigeminal ganglion.

A greater understanding of the wide interpatient variability seen with a subdural block can be derived from knowledge of the ultrastructure of the subdural space. Using electron microscopy, the anatomy of the subdural space was observed by Reina et al¹⁶, wherein the arachnoid mater had an outer compact laminar portion attached to the inside of the dural sac and a separate inner trabeculated portion. Between the laminar arachnoid portion and the dura, a compartment termed the dura-arachnoid interface was seen (Figure 2). This dura-arachnoid interface was seen to be composed of neurothelial cells having relatively few intercellular joints and large intercellular lacunae filled with an amorphous material. This suggested that iatrogenic dissection of this cellular plane can occur if neurothelial cells break up on application of pressure by mechanical forces such as air or fluid injection. Thus fissures can be created within the dura-arachnoid interface, with considerable variability in form¹⁶. While some fissures remain incomplete, some expand towards weaker areas creating a subdural space. Blomberg¹⁷ also documented variability in opening the subdural space under pressure in a cadaveric study. It was observed that while it is easy to open up the subdural space on injection of fluid in up to two-thirds of subjects, it may be difficult or impossible in others.

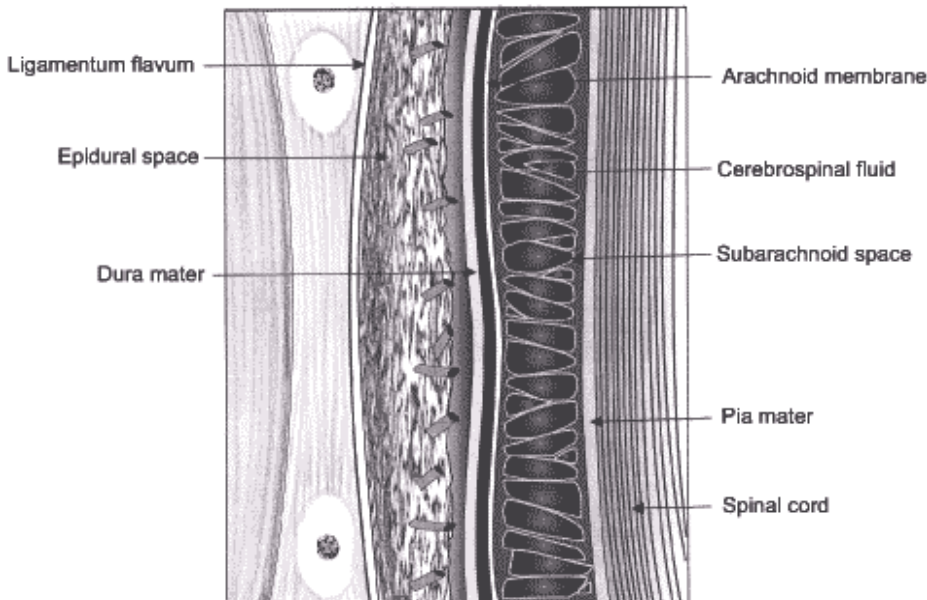


Figure 2: Diagram illustrating dura-arachnoid interface in relation to vertebral arch structures.

INCIDENCE

The first case of radiologically confirmed accidental subdural block was published in 1975². Although a number of case reports of accidental subdural injection have been published since then, the incidence of this complication after epidural is usually considered low. A retrospective study of 2182 consecutive lumbar

epidurals showed an incidence of 0.82%¹⁸. In this study, identification of subdural block was based on the clinical findings only. Hoftman and Ferrante, while analysing radiologically proven cases of subdural block in order to develop a diagnostic algorithm, were able to find 70 such cases published up to February 2007¹⁹.

Most of the reported cases of accidental subdural blockade have been in obstetric patients receiving neuraxial analgesia for labour^{3,6,20-23}. Jenkins, in a prospective study of 145,550 obstetric epidurals performed over a period of 17 years, found the incidence of subdural injection to be one in 4200 (0.024% [95% confidence interval 0.017 to 0.033%])²⁴. In this study, the subdural injection was diagnosed in cases of unexpectedly high block, often asymmetric and involving the face and arms, but with sacral sparing. No radiological confirmation was used for the diagnosis.

Mehta and Salmon confirmed the accuracy of epidural needle placement by X-ray monitoring in 100 patients. According to their findings, up to 7% of epidural needles may be partly placed in the subdural space during the performance of an epidural block²⁵. Thus the actual incidence may be much higher than reported in studies using only clinical criteria for diagnosis.

Although the accidental subdural placement of local anaesthesia has been acknowledged as a potential cause of failed subarachnoid anaesthesia²⁶, the exact incidence of subdural injection while performing subarachnoid block is unknown. However, an incidence ranging from 1 to 13% of accidental subdural injection during contrast myelography has been reported by various authors^{18,27-30}.

During subarachnoid anaesthesia the dura mater is intentionally pierced, with the subdural space being traversed before piercing the arachnoid mater. Therefore, the chances of placing the needle in the subdural space may be greater than with epidural anaesthesia²⁰. Long-bevelled needles used during subarachnoid block may further increase the chance of part placement in the subdural space³¹. However, certain authors believe that subdural localisation is more likely with an epidural needle, as the comparatively blunt epidural needle may pierce the dura without piercing the arachnoid mater¹⁸.

PREDISPOSING FACTORS

A number of factors predisposing to the development of a subdural block have been identified.

Accidental subdural injection is more likely with difficult block placement^{4,32}. Rough handling and rotation of an epidural needle in the epidural space may cause dural laceration, leading to a possibility of subdural placement of the catheter⁴. Subdural placement may occur however, independently of the level of experience of the operator¹⁷. For the treatment of intractable cervical pain, Mehta and Maher¹⁰ injected local anaesthetic in the subdural space; they rotated the epidural needle through an arc of 180° along with gentle pressure to enter the subdural space. In our opinion, the practice of rotating the epidural needle in the epidural space in order to insert the catheter cephalic or caudad can predispose to dural puncture.

Lubenow et al, following their retrospective study, stated that patients having previous back surgery were potentially more prone to accidental subdural injection, because of altered anatomy secondary to scarring and retraction and possible obliteration of the epidural space¹⁸. However, only 28% of patients identified as having a subdural block had a history of back surgery. Houghton and Chalkiadis also reiterated that epidural anaesthesia in patients who have undergone previous back surgery is associated with a higher incidence of subdural catheterisation³².

A recent lumbar puncture may also predispose to subdural injections³¹. In this situation cerebrospinal fluid (CSF) may leak through the dural rent and distend the subdural space. Any attempt to inject local anaesthetics at the same intervertebral space may cause deposition in the subdural space³¹. This fact is supported also by a study in the radiology literature, which indicates that once the subdural compartment is expanded, it is very difficult to place any subsequent injection into the subarachnoid space²⁸.

PRESENTING FEATURES

A subdural block can have a variable presentation depending upon the extent of the spread of local anaesthetic, which in turn is dictated by the highly variable anatomy of the space itself. The onset of the block is somewhat intermediate between that of a subarachnoid and epidural block, because the nerves in the subdural space are covered with pia and arachnoid maters, as compared to the subarachnoid space where the nerves are sheathed by pia mater only and the epidural space where arachnoid, pia and dura mater envelop the nerves. The block is thus often characterised by a slow onset (approximately 15 to 20 minutes after drug injection) and usually lasts for up to two hours, followed by a full recovery³³. The sensory block produced by subdural injection is usually

high and disproportionate to the volume of drug injected, as the limited capacity of the space results in extensive spread²⁰. On the other hand, the sensory block may be inadequate or completely absent^{8,9}.

There is usually sparing of, or minimal effect on sympathetic and motor functions, due to the relative sparing of the ventral nerve roots¹³. Thus, hypotension is likely to be only moderate³¹. Development of motor weakness is slow and less profound, with progressive respiratory inco-ordination rather than sudden apnoea³³. This presentation helps to distinguish an unexpectedly high sensory level due to subdural placement from that caused by an inadvertent subarachnoid placement during epidural anaesthesia, wherein the onset is fast with complete bilateral sympathetic, sensory and motor blockade below a certain level.

A number of unusual presentations of subdural blockade have also been described. Significant motor weakness in the intercostal muscles^{13,20} and upper extremities^{4,5,15}; a faster than usual onset of block^{18,21} and a delayed onset of up to 30 minutes with unduly prolonged blockade³⁴ have been reported. Subdural blockade leading to significant hypotension has also been observed^{4,6,7}. These differences could be explained by the amount of drug actually injected into the subdural space and interpatient variation in the anatomy and distensibility of the space. Unilateral blocks are common with subdural injection^{5,6} and may be a more likely cause for this phenomenon than a dorsomedian band in the epidural space³⁵. On rare occasions, permanent neural damage can occur as a result of unintentional subdural injection³, due to the compression of nerve roots or the radicular arteries traversing the space, causing ischaemia of neural tissues. Though the amount of fluid in the subdural space likely to cause neural damage is not known, a small volume can produce a significant space-occupying lesion if it is placed into a space with low distensibility. Because the subdural space extends intracranially, local anaesthetic block of the brainstem is also possible and periods of unconsciousness and apnoea lasting several hours have been reported³⁶.

Horner's syndrome^{22,23,37} and trigeminal nerve palsy^{5,20,38} have been reported following subdural catheterisation. A trigeminal nerve palsy is a more serious consequence than Horner's syndrome, because this could signify cephalad spread of the anaesthetic agent into the cranial cavity. Involvement of trigeminal nerves is difficult to explain however, as the trigeminal ganglion is contained within Meckel's cavity posterolateral to the cavernous sinus. Meckel's cavity is an arachnoid pouch containing CSF that protrudes from the posterior cranial fossa. At this point the dura and arachnoid mater are separately attached to the ganglia. Therefore, a drug in the subarachnoid or subdural space can affect transmission through the ganglion (Figure 1B). Extension of the sensory nucleus of the trigeminal nerve down to the C2 level in the spinal cord might also explain its involvement. Motor fibres in the mandibular division of the trigeminal nerve exiting the pons through the posterior fossa may also be blocked³⁹.

MECHANISMS

The various mechanisms by which an accidental subdural block can occur while performing central neuraxial blockade include the following:

The epidural needle may pierce the dura but not arachnoid, and consequently the epidural catheter, if threaded, enters the subdural space. This is a well known mechanism and a number of case reports are available suggesting subdural placement of intended epidural catheters^{3,4,6,15,23}.

An epidural or spinal needle may pierce the dura as well as the arachnoid, such that it lies partly in both the subarachnoid and the subdural spaces. Stevens and Stanton-Hicks³¹ speculated on the possibility of this misplacement. In this scenario, drug injection distributes preferentially to the subdural rather than the subarachnoid space³¹ despite the ability to aspirate CSF. These authors suggested this may be due to the CSF leaking into and distending the subdural space.

An epidural catheter may migrate subdurally. It has been observed that catheters migrate inwards at almost twice the incidence of outward migration⁴⁰. Following initial successful epidural analgesia, subsequent subdural migration has been reported^{20,41}. The clinical presentation of subdural block was observed approximately 10 hours after adequate epidural analgesia in one of these case reports, while in another it was noticed four days after epidural infusion. In both these reports the subdural position of the catheter was confirmed radiologically. Hardy, in his study performed on postmortem dura and arachnoid mater, demonstrated an inability of soft epidural catheters to penetrate dura mater⁴². However, it is possible that physical characteristics of postmortem dura may not be the same as that in a live patient. In our opinion, migration of an epidural catheter across the dura is difficult but possible, particularly during prolonged catheterisation.

The use of multi-hole epidural catheters may predispose to a subdural block by potential placement across more than one compartment. This mechanism was proposed by Reynolds and Speedy³⁵. The catheter position relative to the dura and the pressures used during injection of the drug may affect the orifice from which the drug is ejected⁴³. Thus, a particular dose of local anaesthetic may produce a composite subarachnoid, subdural and/or extradural blockade, depending upon the pressure used to inject the drug. In their in vitro study, Power and Thorburn⁴⁴ observed that fluid from low-flow infusions through multi-hole catheters passed from the proximal hole, but with more rapid infusions it exited from distal holes. This phenomenon has been suggested to be a cause of late clinical manifestation of subdural block when continuous low flows are used after a bolus through multi-hole epidural catheters³².

DIAGNOSIS

Accidental injection into the subdural space should be suspected if a less than distinct loss of resistance is felt on inserting the needle into the epidural space or if the patient complains of a frontal headache³ (due to the intracranial displacement of CSF at the time of drug injection). Lubenow et al described two major and three minor clinical criteria for the diagnosis of a subdural block¹⁸. Major criteria included a negative aspiration test and unexpected extensive sensory block, while minor criteria included a delayed onset by 10 minutes or more of a sensory or motor nerve block, a variable motor block and sympatholysis out of proportion to the administered dose of local anaesthetic. A subdural injection should be considered to have occurred if both of the major criteria and at least one minor criterion are present.

Recently, another diagnostic algorithm was proposed by Hoftman and Ferrante¹⁹. They analysed the clinical presentation of all the radiologically proven cases of subdural block and suggested a four-step diagnostic algorithm to detect subdural block. In the first step, the performer determines whether the block is presumed to be the epidural or subarachnoid space based on the tactile feel during the insertion and the presence or absence of CSF. In the second step, dermatomal spread is assessed as excessive, restricted or neither. In the third step, minor criteria such as onset >20 minutes, cardiovascular stability, motor sparing, patchy or asymmetrical spread, respiratory failure and cranial involvement are applied. The authors stated that incorporating all types of presentations increased the sensitivity and utility of this algorithm when compared to other diagnostic criteria.

The subdural placement of an epidural catheter can be confirmed radiologically using X-ray^{4,20,23}, computed tomography scan³ or magnetic resonance imaging²². As the subdural space is a potential space and normally not visible on scans, the presence of deliberately injected contrast media or fluid in the space is required to confirm the subdural placement. The subdural injection of contrast media is seen as a dense collection confined to the posterior aspect of the spinal canal, spreading mainly in a cephalad direction. A small amount of contrast may extend laterally, delineating the nerve roots. The spread is not affected by a change in posture²⁸ and can be unilateral. On an anteroposterior view of the lumbar spine X-ray, the appearance of subdural contrast medium is similar to subarachnoid contrast media. However, on lateral view and computed tomography scan the difference is appreciable. Contrast in the subarachnoid space rapidly descends in the CSF with gravity and outlines the exiting nerve roots. The CSF dilutes contrast and it appears less opaque than subdural contrast. With epidural injection of contrast media, a wide distribution is seen which tends to flow outward through the intervertebral foramina.

It has been argued that radiological confirmation of a subdural catheter has no therapeutic benefit and is hence unnecessary and may contribute further to complications²¹. Moreover, computed tomography and magnetic resonance imaging scans are not always possible for confirmation of catheter position.

Electrical stimulation of the epidural catheter has been used to diagnose subdural placement⁴⁵. The fluid injected into the subdural space can spread a considerable distance, thus a diffuse motor response involving multiple segments can potentially be elicited at a low current (<1 mA).

MANAGEMENT OF SUBDURAL BLOCK

There are no clear guidelines for the management of a potential subdural catheter. A patient with an accidental subdural block should be monitored closely and if a high sensory level develops, in conjunction with cardiovascular and respiratory support, patients should be reassured that this is a reversible and temporary event. The epidural catheter should be removed and if mandatory, be relocated to another space. If a subarachnoid block is planned, enhanced cephalad spread of local anaesthetic should be anticipated, because of the potential compression of the subarachnoid space by the subdural injection⁴⁶. If general anaesthesia is

administered, succinylcholine should be used with caution as it may induce severe bradycardia in the presence of a high sympathetic block⁴⁷.

There is evidence to support the use of inadvertently inserted subdural catheters to provide continued analgesia^{21,37,48}. There are potential problems with this approach as the sensory level is difficult to predict and it may not provide adequate analgesia in all the required dermatomes. Also, the presence of a catheter in the subdural space may cause arachnoid rupture, particularly on injection of a large dose, leading to the risk of a post-dural puncture headache and leakage of local anaesthetic producing a subarachnoid block.

PREVENTION

Unrecognised subdural placement of epidural needle or catheter may account for many complications. A number of precautions can be taken in order to avoid or detect subdural placement:

Care should be taken when rotating a Tuohy needle once it has entered the epidural space.

There should be a high index of suspicion of subdural placement in patients with difficult block or previous back surgery.

Once the dura mater has been punctured, it may be advisable to choose another interspace if a repeat neuraxial block is required on the same occasion.

During continuous epidural catheter techniques, every top-up should be given in a fractionated manner, as per usual safe practice.

Single orifice catheters may be preferable to multiple orifice catheters.

Anaesthesia personnel should be aware of the presentation of subdural block so that it can be diagnosed and managed in a timely manner.

CONCLUSION

All anaesthetists should be aware of the possibility of subdural block during central neuraxial anaesthesia. The differential diagnosis of a possible subdural injection should be considered in cases of extensive sensory blockade despite apparently small volumes of epidurally administered local anaesthetics, unexpected failure of block or atypical presentations following otherwise uncomplicated regional block. Once subdural injection is suspected, it is advisable to avoid further local anaesthetic injections through the catheter and the patient should be monitored carefully for any adverse effects.

REFERENCES

1. Fischer B, Chaudhari M. Techniques of epidural block. *Anaesth Intensive Care Med* 2006; 7:422-426 [PubMed]
2. Boys JE, Norman PF. Accidental subdural analgesia: A case report, possible clinical implication and relevance to "massive extradurals". *Br J Anaesth* 1975; 47:1111-1113 [PubMed]
3. McMenemin IM, Sissons GR, Brownridge P. Accidental subdural catheterization: Radiological evidence of a possible mechanism for spinal cord damage. *Br J Anaesth* 1992; 69:417-419 [PubMed]
4. Asato F, Nakatani K, Matayoshi Y, Katekawa Y, Chinen K. Development of a subdural motor blockade. *Anaesthesia* 1993; 48:46-49 [PubMed]
5. Manchanda VN, Murad SH, Shilyansky G, Mehringer M. Unusual clinical course of accidental subdural local anesthetic injection. *Anesth Analg* 1983; 62:1124-1126 [PubMed]
6. Smith GB, Barton FL, Watt JH. Extensive spread of local anaesthetic solution following subdural insertion of an epidural catheter during labour. *Anaesthesia* 1984; 39:355-358 [PubMed]
7. Kalil A. Unintended subdural injection: a complication of epidural anesthesia – a case report. *AANA J* 2006; 74:207-211 [PubMed]
8. Collier CB. Accidental subdural injection during attempted lumbar epidural block may present as a failed or inadequate block: Radiographic evidence. *Reg Anesth Pain Med* 2004; 29:45-51 [PubMed]
9. Van der Maaten JM, van Kleef JW. Failure of anaesthesia after accidental subdural catheter placement. *Acta Anaesthesiol Scand* 1992; 36:707-709 [PubMed]
10. Mehta M, Maher R. Injection into the extra-arachnoid subdural space. Experience in the treatment of intractable cervical pain and in the conduct of extradural (epidural) analgesia. *Anaesthesia* 1977; 32:760-766 [PubMed]
11. Gray H. *Anatomy of the human body*, 30th ed. Lea & Febiger, Philadelphia 1985; p. 1125
12. Shapiro R. *Myelography*, 3rd ed. Year Book Medical Publishers, Chicago 1975; p. 124

13. Soni W, Holland R. An extensive lumbar epidural block. *Anaesth Intensive Care* 1981; 9:150-153 [PubMed]
14. Romanes GJ. *Cunningham's Manual of Practical Anatomy*, 14th ed. Oxford University Press, Oxford 1986; p. 195-196
15. Pearson RMG. A rare complication of extradural analgesia. *Anaesthesia* 1984; 39:460-463 [PubMed]
16. Reina MA, De Leon Casasola O, López A, De Andrés JA, Mora M, Fernández A. The origin of the spinal subdural space: ultrastructure findings. *Anesth Analg* 2002; 94:991-995 [PubMed]
17. Blomberg RG. The lumbar subdural extraarachnoid space of humans: an anatomical study using spinaloscopy in autopsy cases. *Anesth Analg* 1987; 66:177-180 [PubMed]
18. Lubenow T, Keh-Wong E, Kristof K, Ivankovich O, Ivankovich AD. Inadvertent subdural injection: a complication of an epidural block. *Anesth Analg* 1988; 67:175-179 [PubMed]
19. Hoftman NN, Ferrante FM. Diagnosis of unintentional subdural anesthesia/analgesia: analyzing radiographically proven cases to define the clinical entity and to develop a diagnostic algorithm. *Reg Anesth Pain Med* 2009; 34:12-16 [PubMed]
20. Abouleish E, Goldstein M. Migration of an extradural catheter into the subdural space. A case report. *Br J Anaesth* 1986; 58:1194-1197 [PubMed]
21. Bell GT, Taylor JC. Subdural block-further points. *Anaesthesia* 1994; 49:794-795 [PubMed]
22. Ralph CJ, Williams MP. Subdural or epidural? Confirmation with magnetic resonance imaging. *Anaesthesia* 1996; 51:175-177 [PubMed]
23. Lee A, Dodd KW. Accidental subdural catheterisation. *Anaesthesia* 1986; 41:847-849 [PubMed]
24. Jenkins JG. Some immediate serious complications of obstetric epidural analgesia and anaesthesia: a prospective study of 145 550 epidurals. *Int J Obstet Anesth* 2005; 14:37-42 [PubMed]
25. Mehta M, Salmon N. Extradural block. Confirmation of the injection site by X ray monitoring. *Anaesthesia* 1985; 40:1009-1012 [PubMed]
26. Sechzer PH. Subdural space in spinal anesthesia. *Anesthesiology* 1963; 24:869-870 [PubMed]
27. Jones MD, Newton TH. Inadvertent extra-arachnoid injections in myelography. *Radiology* 1963; 80:818-822 [PubMed]
28. Schultz EH Jr, Brogdon BG. The problem of subdural placement in myelography. *Radiology* 1962; 79:91-95 [PubMed]
29. Dake MD, Dillon WP, Dorwart RH. CT of extraarachnoid metrizamide instillation. *AJR Am J Roentgenol* 1986; 147:583-586 [PubMed]
30. Milants WP, Parizel PM, de Moor J, Tobback IG, De Schepper AM. Epidural and subdural contrast in myelography and CT myelography. *Eur J Radiol* 1993; 16:147-150 [PubMed]
31. Stevens RA, Stanton-Hicks MA. Subdural injection of local anesthetic: a complication of epidural anesthesia. *Anesthesiology* 1985; 63:323-326 [PubMed]
32. Haughton AJ, Chalkiadis GA. Unintentional paediatric subdural catheter with oculomotor and abducens nerve palsies. *Paediatr Anaesth* 1999; 9:543-548 [PubMed]
33. Collier C. Total spinal or massive subdural block. *Anaesth Intensive Care* 1982; 10:92-93 [PubMed]
34. Conklin KA, van der Wal C. Epidural anaesthesia with chloroprocaine. Delayed onset, extensive spread, and prolonged duration. *Anaesthesia* 1980; 35:202-204 [PubMed]
35. Reynolds F, Speedy HM. The subdural space: the third place to go astray. *Anaesthesia* 1990; 45:120-123 [PubMed]
36. Collier CB. Accidental subdural block: four more cases and a radiographic review. *Anaesth Intensive Care* 1992; 20:215-225 [PubMed]
37. Rodríguez J, Bárcena M, Taboada-Muñiz M, Alvarez J. Horner syndrome after unintended subdural block. A report of 2 cases. *J Clin Anesth* 2005; 17:473-477 [PubMed]
38. De la Gala F, Reyes A, Avellanal M, Baticón P, González-Zarco LM. Trigeminal nerve palsy and Horner's syndrome following epidural analgesia for labor: a subdural block? *Int J Obstet Anesth* 2007; 16:180-182 [PubMed]
39. Gray H. *Anatomy of human body*, 29th ed. Lea and Febiger, Philadelphia 1975; p. 815-816
40. Phillips DC, Macdonald R. Epidural catheter migration during labour. *Anaesthesia* 1987; 42:661-663 [PubMed]

41. Hartrick CT, Pither CE, Pai U, Raj PP, Tomsick TA. Subdural migration of an epidural catheter. *Anesth Analg* 1985; 64:175-178 [PubMed]
42. Hardy PA. Can epidural catheters penetrate dura mater? An anatomical study. *Anaesthesia* 1986; 41:1146-1147 [PubMed]
43. Ward CF, Osborne R, Benumof JL, Saidman LJ. A hazard of double-orifice epidural catheters. *Anesthesiology* 1978; 48:362-364 [PubMed]
44. Power I, Thorburn J. Differential flow from multihole epidural catheters. *Anaesthesia* 1988; 43:876-878 [PubMed]
45. Tsui BC, Gupta S, Emery D, Finucane B. Detection of subdural placement of epidural catheter using nerve stimulation. *Can J Anaesth* 2000; 47:471-473 [PubMed]
46. Chen SH, Chiueh HY, Hung CT, Tsai SC, Wong SY. Extensive sensory block caused by accidental subdural catheterization during epidural labor analgesia. *Chang Gung Med J* 2006; 29:607-611 [PubMed]
47. Rowbottom SJ. Continuous subdural block. *Br J Anaesth* 1993; 71:607 [PubMed]