Pictorial Essay

Sonography of Peripheral Nerve Pathology

R. M. Stuart[1], E. S. C. Koh[1], W. H. Breidahl[1,2]

In 1988, Fornage [1] produced the first review of imaging findings of peripheral nerves using sonography. Continual technologic improvements, including the availability of high-frequency transducers (6-13–MHz) and variable footprint sizes, have led to an increase in the use of sonography in the imaging of peripheral nerves [2–4]. We believe that sonography should be the primary technique for imaging peripheral nerve pathology because it is inexpensive and widely available, has no contraindications, and allows rapid, detailed imaging of the entire length of the major peripheral nerves of both limbs.

In our practice, we routinely use a 5-12–MHz linear array transducer (HDI 5000, ATL, Bothell, WA) to scan the entire peripheral nerve in both transverse and longitudinal planes. Normal peripheral nerves have a typical sonographic appearance, showing multiple longitudinal hypoechoic bands, which represent fascicular bundles. These are separated by discontinuous bands of increased echogenicity, corresponding to the surrounding epineurium [1, 3] (Fig. 1A). In this article, we describe the sonographic appearances of normal peripheral nerves and important examples of peripheral nerve disorders.

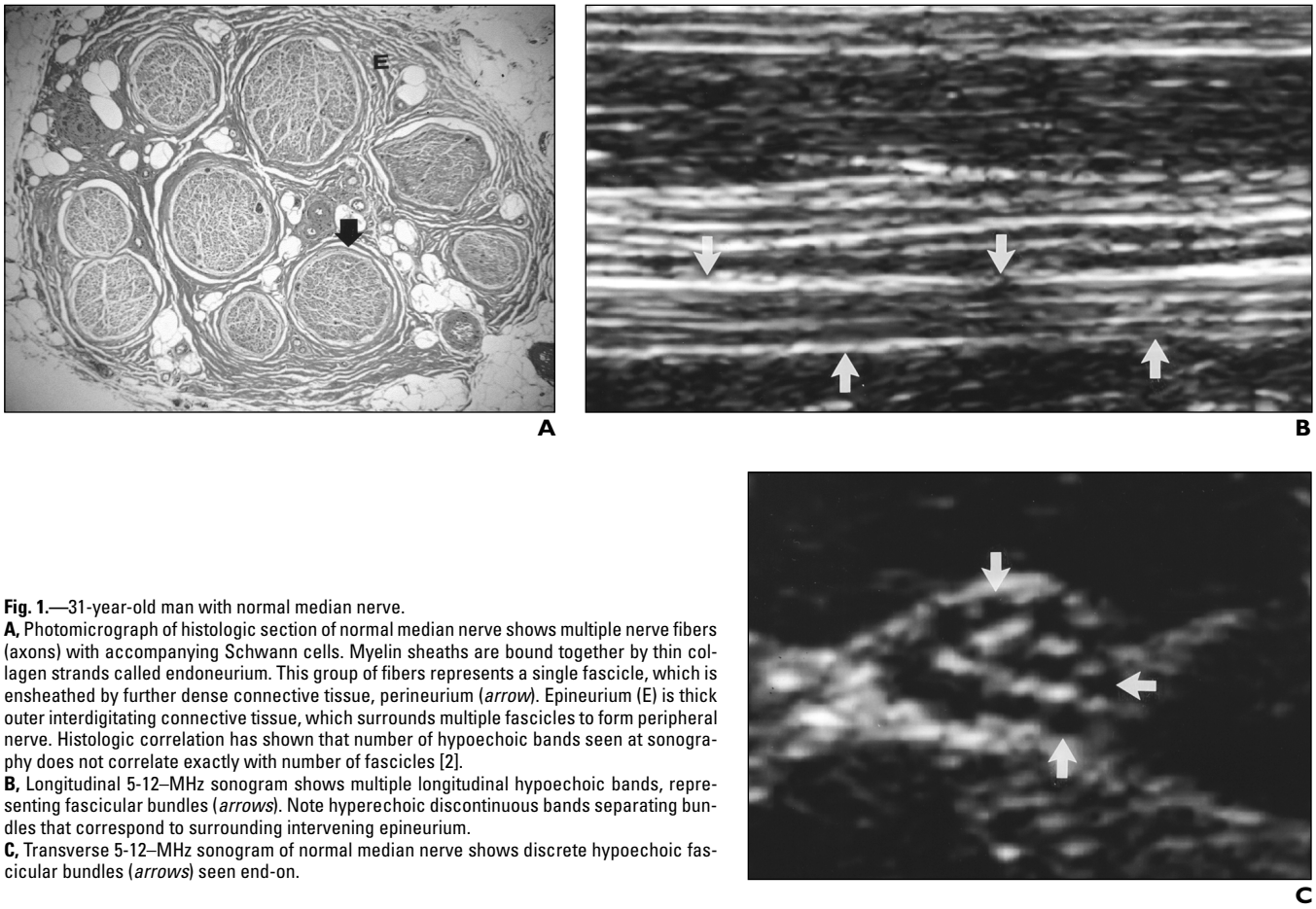

Fig. 1.—31-year-old man with normal median nerve.
A, Photomicrograph of histologic section of normal median nerve shows multiple nerve fibers (axons) with accompanying Schwann cells. Myelin sheaths are bound together by thin collagen strands called endoneurium. This group of fibers represents a single fascicle, which is ensheathed by further dense connective tissue, perineurium (*arrow*). Epineurium (E) is thick outer interdigitating connective tissue, which surrounds multiple fascicles to form peripheral nerve. Histologic correlation has shown that number of hypoechoic bands seen at sonography does not correlate exactly with number of fascicles [2].
B, Longitudinal 5-12–MHz sonogram shows multiple longitudinal hypoechoic bands, representing fascicular bundles (*arrows*). Note hyperechoic discontinuous bands separating bundles that correspond to surrounding intervening epineurium.
C, Transverse 5-12–MHz sonogram of normal median nerve shows discrete hypoechoic fascicular bundles (*arrows*) seen end-on.

Received July 15, 2002; accepted after revision May 14, 2003.

[1]Department of Diagnostic and Interventional Radiology, Royal Perth Hospital, GPO Box X2213, Wellington St., Perth 6847, Western Australia.

[2]Perth Radiological Clinic, 127 Hamersley Rd., Subiaco, Perth 6008, Western Australia. Address correspondence to W. H. Breidahl (billbrei@perthradclinic.com.au).

AJR 2004;182:123–129 0361–803X/04/1821–123

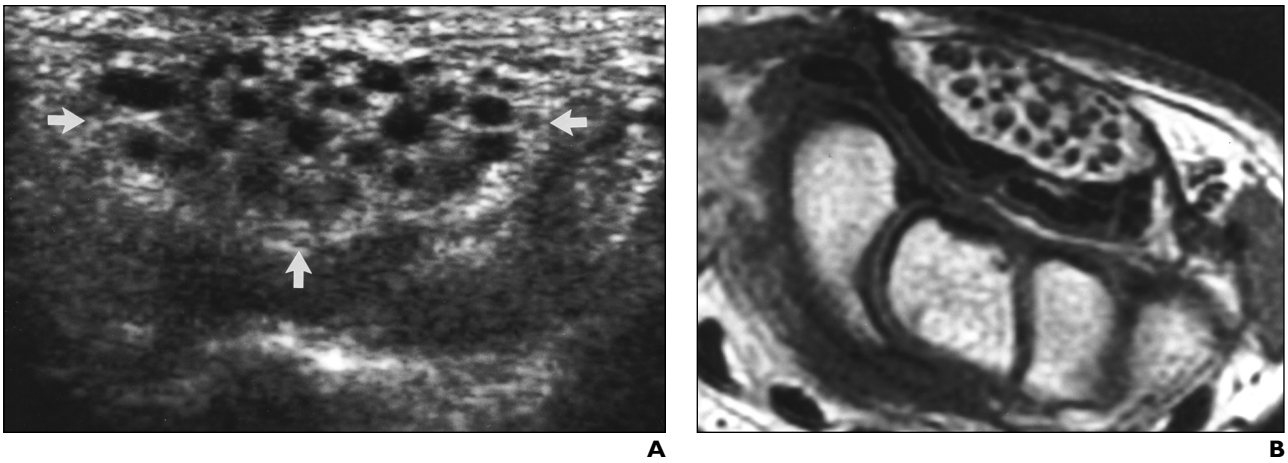

Fig. 2.—13-year-old girl with neural fibrolipoma of median nerve.
A, Transverse 5-12–MHz sonogram shows enlarged hypoechoic fascicles separated by extensive echogenic (fatty) infiltrate (*arrows*).
B, Axial T1-weighted image (TR/TE, 500/14) shows cablelike thick hypointense bands separated by abundant fatty tissue, all of which are diagnostic of neural fibrolipoma.

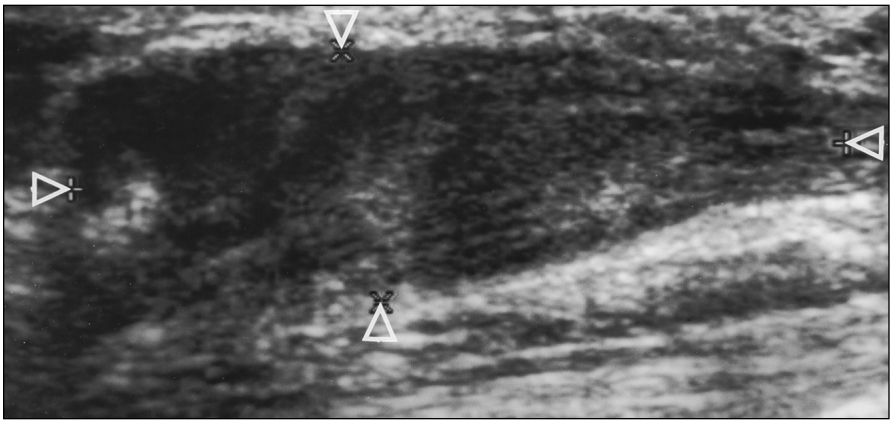

Fig. 3.—41-year-old man with traumatic neuroma. Longitudinal 5-12–MHz sonogram shows localized swelling of tibial nerve (*arrowheads*) at site of iatrogenic injury.

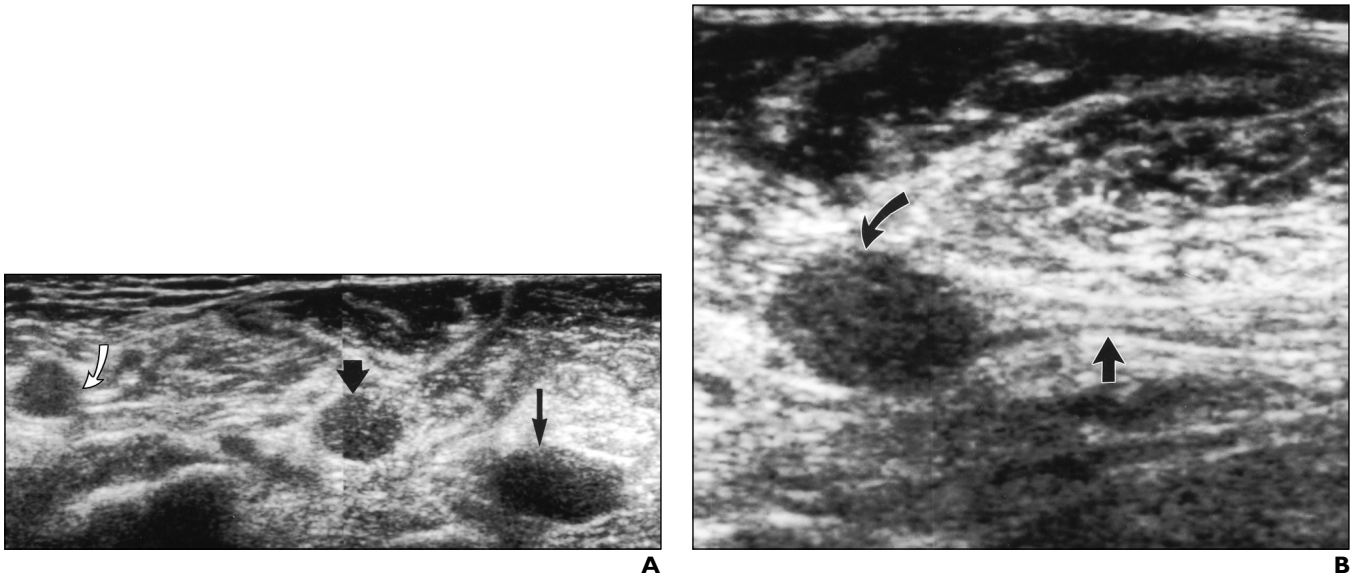

Fig. 4.—30-year-old man with pain after forearm amputation for undifferentiated sarcoma.
A, Compound transverse 5-12–MHz sonogram of proximal forearm shows three enlarged, well-defined, ovoid hypoechoic masses at amputated ends of ulnar (*thin black arrow*), median (*thick black arrow*), and superficial branch of radial (*white arrow*) nerves.
B, Longitudinal 5-12–MHz image of central-most of three hypoechoic masses shows median nerve (*straight arrow*) extending to neuroma (*curved arrow*). Follow-up imaging (not shown) at 6 months revealed no change.

Focal Intrinsic Neural Lesions

Neural Fibrolipoma

Neural fibrolipoma is a disorder of unknown origin that causes infiltration of the perineurium and epineurium with fibrofatty tissue. More than 80% of cases involve the median nerve, although the brachial plexus, ulnar, radial, and peroneal nerves may also be affected. When neural fibrolipoma is associated with unilateral macrodactyly, it is termed "macrodystrophia lipomatosa" and tends to affect the second or third digit of the hand or foot. There is extensive fatty infiltration of the nerve and the whole digit, with accompanying osseous overgrowth. Sonography shows thickened alternating hyperechoic and hypoechoic bands, reflecting the fibrofatty infiltrate [2, 3] (Fig. 2).

Traumatic Neuroma

Traumatic neuromas are proliferative masses that represent a disorganized attempt at nerve regeneration. They are often clinically palpable as small, firm, tender masses. Spindle neuromas are a focal fusiform mass occurring in intact nerves caused by chronic irritation. Terminal (amputation) neuromas result from partial or complete transection of the nerve and arise at the proximal nerve end. The most common site of occurrence is in the lower limbs after surgical amputation. Because of their fibrous capsule, traumatic neuromas are usually well defined and hypoechoic with attenuation characteristics similar to muscle [1, 3] (Figs. 3 and 4).

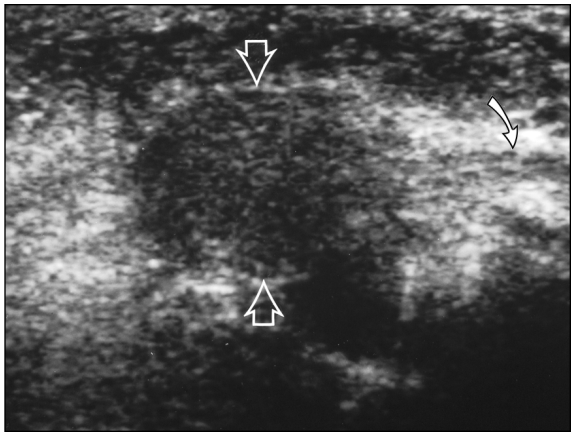

Fig. 5.—24-year-old woman with surgically excised Morton's neuroma. Preoperative longitudinal 5–12 MHz sonogram shows discrete oval hypoechoic mass (*open arrows*), lying between metatarsal heads. Digital nerve (*solid arrow*) can be seen proximal to mass.

Morton's Neuroma

The term "Morton's neuroma" is a misnomer that describes a benign mass of perineural fibrosis involving a plantar digital nerve lying between two metatarsal heads. Morton's neuromas may be multiple and bilateral and most commonly occur between the heads of the third and fourth metatarsals; they are likely to develop because of friction of the nerve against the transverse intermetatarsal ligament. On sonography, an ovoid hypoechoic compressible mass is visible in the intermetatarsal space [2, 3] (Fig. 5). Fluid within the intermetatarsal bursae is a common associated finding affecting the first three web spaces that may also be seen on sonography [5].

Intraneural Perineuroma

Intraneural perineuroma is a rare focal neural lesion that causes a slowly progressive painless mononeuropathy. Histologic and cytogenetic analyses reveal onion bulb–shaped whorls of neoplastic perineural cell proliferation. The region of the peripheral nerve abnormality can be determined using electromyography and nerve conduction studies [6]. Sonography shows the lesion to be hypoechoic, with mildly elongated fusiform enlargement of the involved nerve (Fig. 6).

Peripheral Nerve Sheath Tumors

The benign peripheral nerve sheath tumors that are most commonly described are

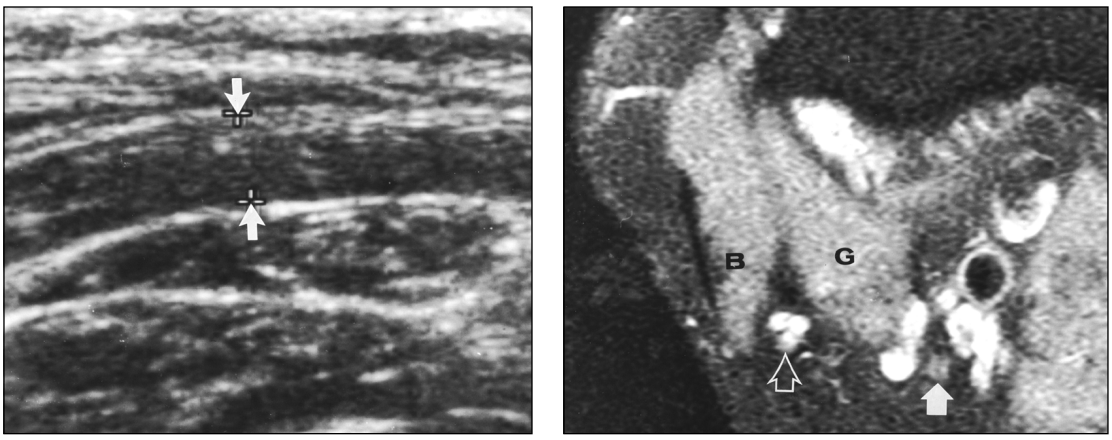

Fig. 6.—34-year-old man with intraneural perineuroma diagnosed after surgical biopsy.
A, Longitudinal 5-12–MHz sonogram shows fusiform hypoechoic swelling of right common peroneal nerve (*arrows*).
B, Axial STIR MRI shows intraneural perineuroma of common peroneal nerve at level of proximal popliteal fossa, with enlarged hyperintense fasciculi (*open arrow*) between biceps femoris muscle (B) and lateral head of gastrocnemius muscle (G). Compare with healthy tibial nerve (*solid arrow*) between veins.

the schwannoma and the neurofibroma. Schwannomas are encapsulated tumors that grow eccentrically along the nerve axis, within the epineurium, thus often allowing the tumor to be surgically excised without loss of neurologic function. Neurofibromas most commonly arise sporadically, either in a diffuse cutaneous form or as a solitary peripheral nerve tumor. The plexiform neurofibroma is a rarer neoplasm that typically infiltrates the fascicular bundles of large nerve trunks and is virtually pathognomonic of neurofibromatosis 1. These tumors are surgically inseparable from the host nerve and can undergo malignant transformation [1–3].

Sonography is unreliable in distinguishing between schwannomas and neurofibromas;

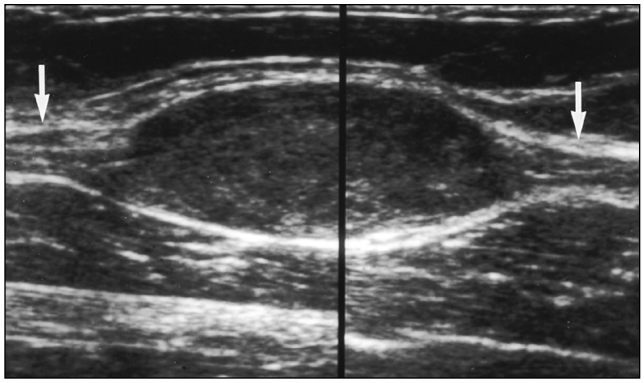

Fig. 7.—32-year-old man with schwannoma. Longitudinal composite 5-12–MHz sonogram of ulna nerve in upper arm shows elongated hypoechoic mass with healthy nerve entering and exiting tumor (*arrows*). Diagnosis was confirmed at open biopsy.

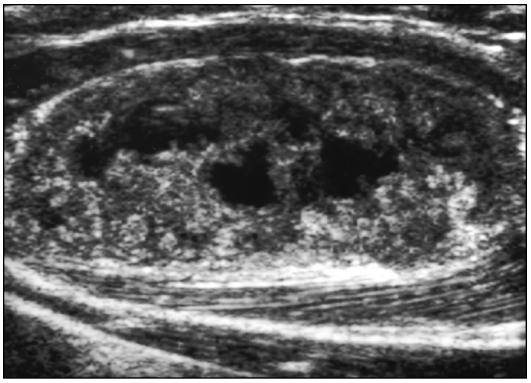

Fig. 8.—38-year-old man with schwannoma. Longitudinal 5-12–MHz sonogram shows cystic degeneration as anechoic spaces in schwannoma of radial nerve, biopsied under sonography guidance.

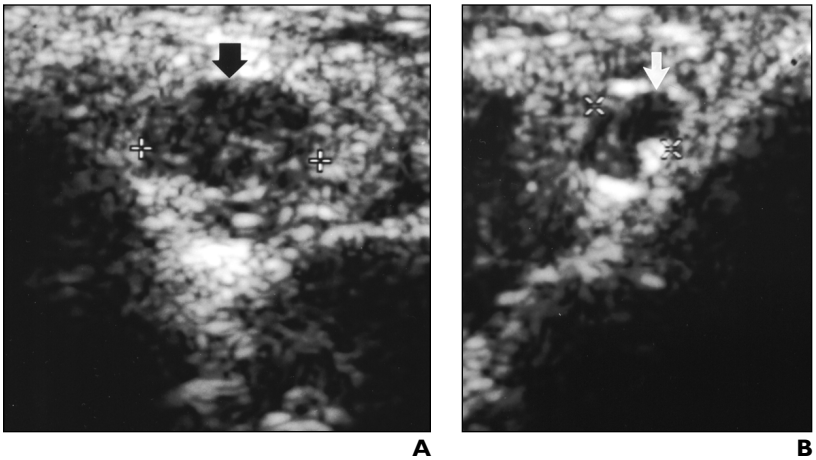

Fig. 9.—43-year-old man with ulnar neuritis.
A, Transverse 5-12–MHz sonogram shows hypoechoic enlargement of right ulnar nerve (*arrow*) in cubital tunnel.
B, Sonogram obtained at same magnification shows normal calibre of contralateral left ulnar nerve (*arrow*) for comparison with **A**. Symptom relief followed ulnar nerve decompression.

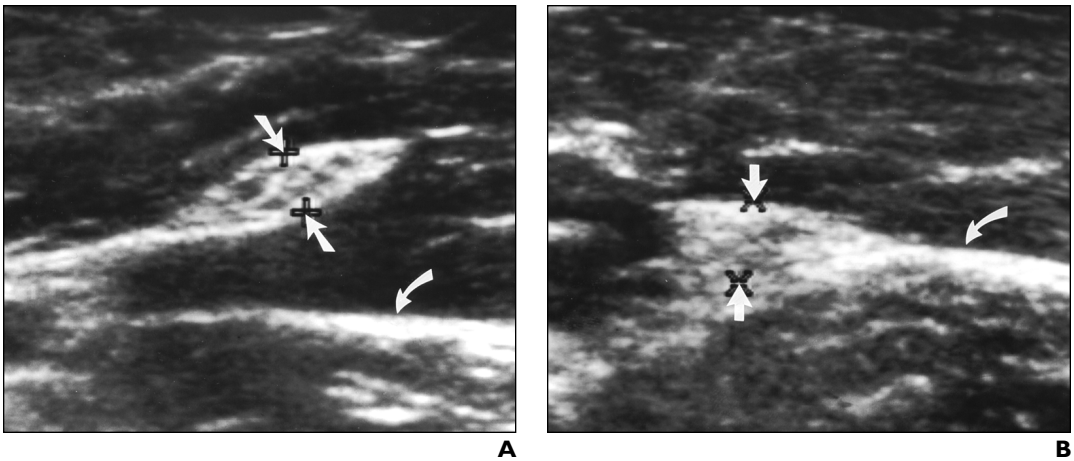

Fig. 10.—31-year-old male bus driver with pronator teres syndrome.
A, Transverse 5-12–MHz sonogram shows aberrant path of right median nerve (*straight arrows*) through humeral head of pronator teres with deep fascia inferiorly (*curved arrow*).
B, Sonogram shows normal left median nerve at same level (*straight arrows*) passes beneath humeral head of left pronator teres with deep fascia again shown (*curved arrow*). Recent change to driving new bus corresponded to onset of symptoms that resolved on return to driving old bus.

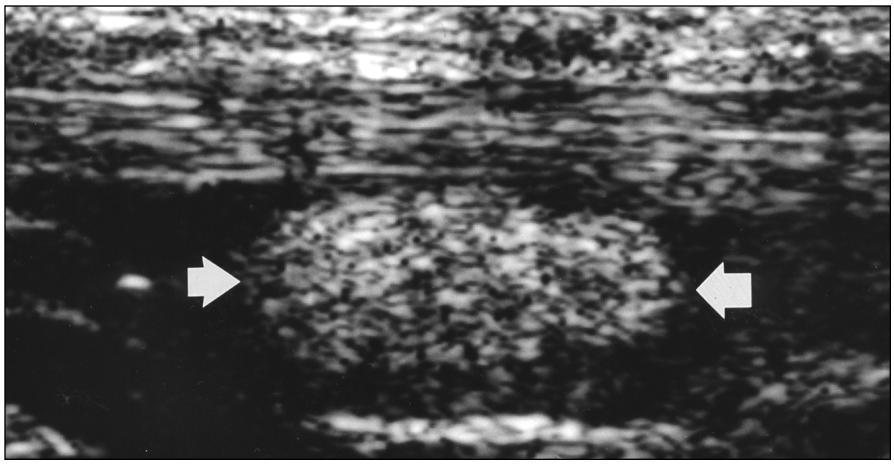

Fig. 11.—39-year-old man with carpal tunnel syndrome. Longitudinal 5-12–MHz sonogram shows echogenic oval mass (*arrows*) found to be tendon sheath fibrolipoma within carpal tunnel at surgery.

both appear as discrete homogeneous ovoid hypoechoic masses, with a healthy nerve at the proximal and distal aspects of the mass (Fig. 7). The presence of cystic degeneration favors schwannoma rather than neurofibroma [1–3] (Fig. 8).

Malignant peripheral nerve sheath tumors arise from the transformation of a plexiform neurofibroma in neurofibromatosis 1 in 50% of cases, although previous radiotherapy can induce the development of these rare and highly malignant tumors. On sonography, they appear as hypoechoic lesions, often with indistinct margins [3].

Nerve Entrapment

As peripheral nerves pass through fibroosseous tunnels, they are vulnerable to compression from a variety of extrinsic causes: congenital, traumatic, synovitis, infiltration, ganglia, tumor, and other acquired disorders. Neural compression leads to ischemia and venous congestion. If chronic, this may cause fibrosis and loss of nerve function with atrophy of the innervated musculature. Clinical manifestations and nerve conduction studies generally give the diagnosis. However, in atypical cases, sonography can show causative extrinsic abnormalities at the site of compression, with associated changes in nerve contour and echotexture [2, 4, 7]. The peripheral nerves that sonography can evaluate in entrapment syndromes include the suprascapular, median, ulnar, radial, sciatic, tibial, and common peroneal nerves (Figs. 9–11).

Nerve Dislocation

As it courses behind the posterior aspect of the elbow, the ulnar nerve normally lies in the cubital tunnel. During elbow flexion, sonography can be used to scan dynamically, showing ulnar nerve dislocation; the nerve

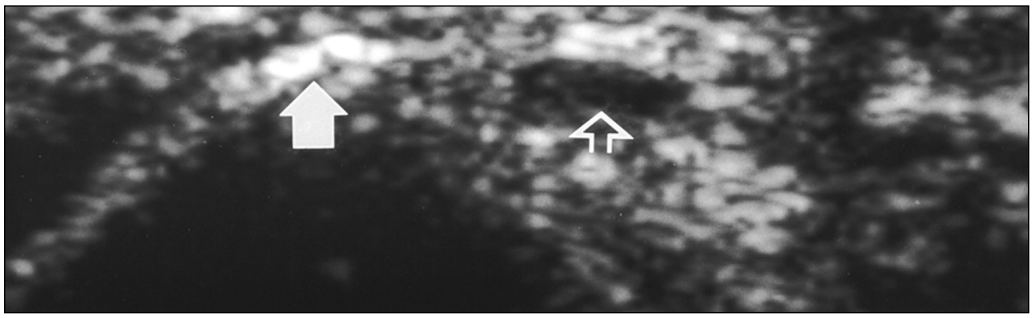

A



B

Fig. 12.—34-year-old man with ulnar nerve dislocation.
A, Transverse 5-12–MHz sonogram of cubital tunnel using small footprint probe shows ulnar nerve (*open arrow*) lying in normal position within sulcus, lateral to medial epicondyle (*solid arrow*) when elbow is extended.
B, Transverse 5-12–MHz sonogram obtained with elbow flexion shows that ulnar nerve (*curved arrow*) dislocates anteromedially out of sulcus (*straight arrow*).

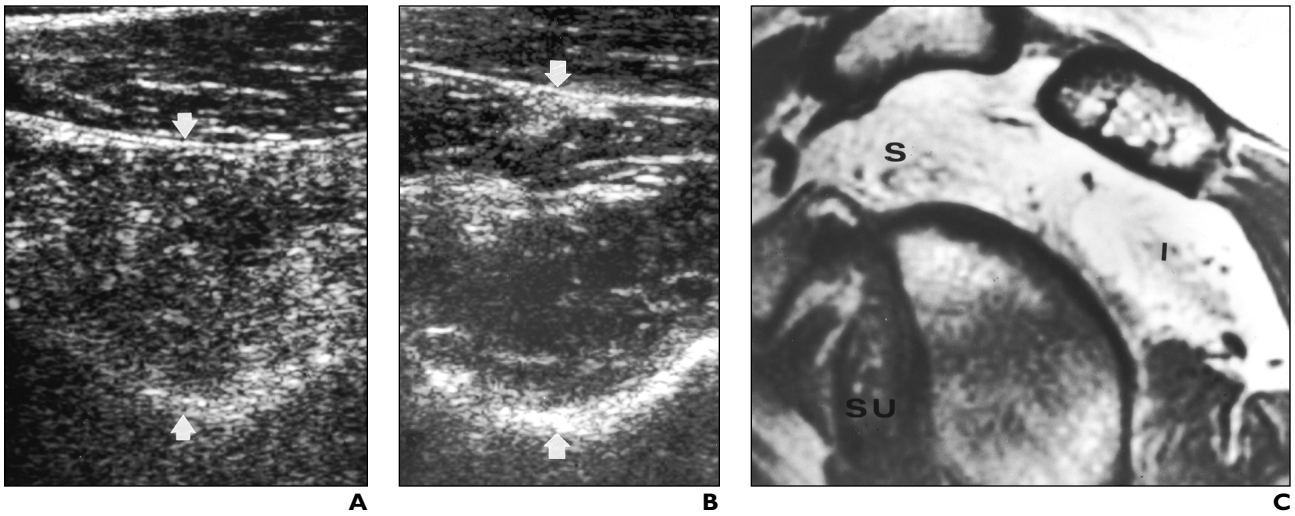

Fig. 13.—47-year-old woman with longstanding brachial neuritis (Parsonage-Turner syndrome).
A, Longitudinal 5-12–MHz sonogram shows increased echogenicity within atrophic right infraspinatus muscle (*arrows*), caused by denervation.
B, Sonogram shows normal echogenicity on contralateral side at same magnification (*arrows*).
C, Sagittal oblique T1-weighted image (TR/TE, 500/14) of same shoulder as in **B** shows atrophy and fatty infiltration of infraspinatus (I) as well as supraspinatus (S) muscles. Subscapularis (SU) muscle bulk is normal.

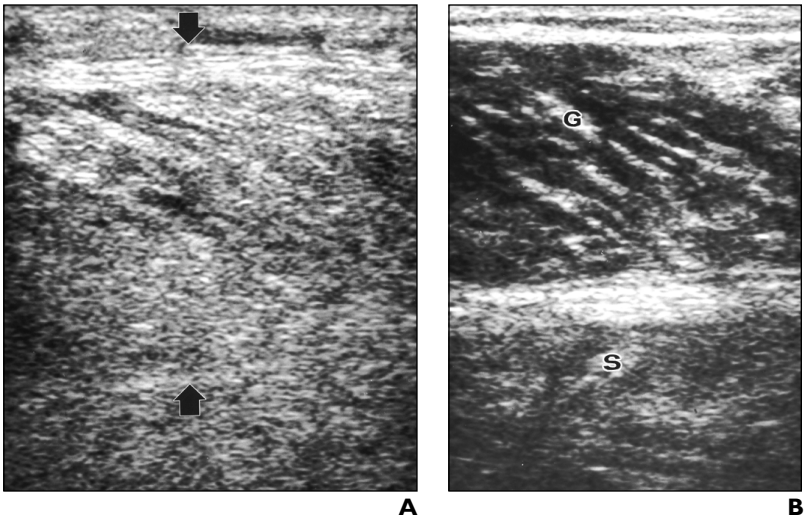

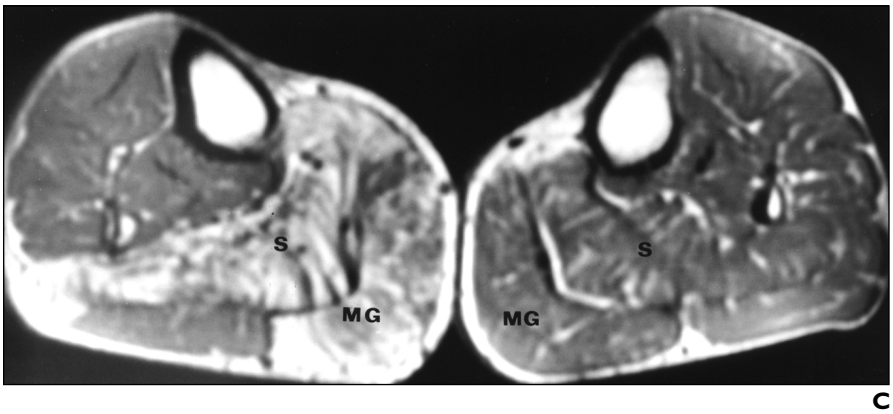

Fig. 14.—60-year-old man with right calf pseudohypertrophy.
A, Longitudinal 5-12–MHz sonogram shows increased echogenicity within gastrocnemius (*arrows*) and soleus muscles of right calf. Increased muscular echogenicity and bulk, caused by fatty infiltration, confirms pseudohypertrophy on sonography.
B, Longitudinal 5-12–MHz sonogram shows normal left gastrocnemius (G) and soleus (S) muscles for comparison.
C, Axial T1-weighted image (TR/TE, 500/14) shows enlargement and fatty replacement within right soleus (S) and gastrocnemius (MG) muscles, compared with healthy left side.

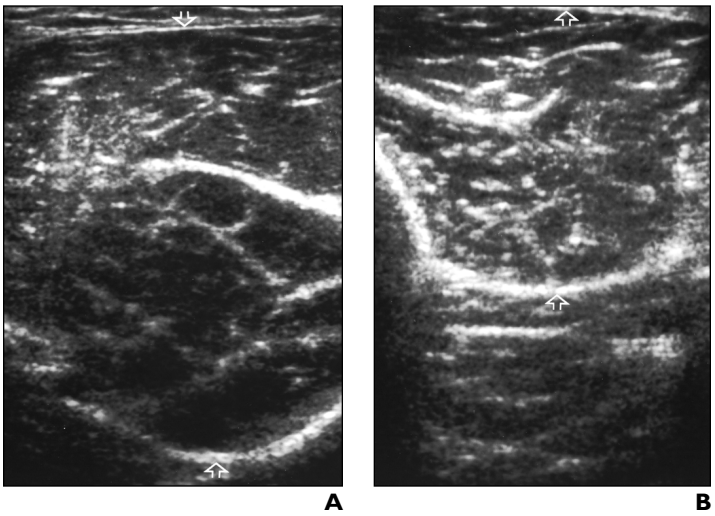

Fig. 15.—35-year-old man with true hypertrophy.
A, Transverse 5-12–MHz sonogram of right calf shows enlargement of tibialis anterior muscle (*arrows*), caused by chronic stimulation of deep peroneal nerve. Normal echogenicity is maintained in hypertrophic muscle.
B, Sonogram shows healthy left calf (*arrows*) at same magnification as **A** for comparison.

becomes displaced around and anterior to the tip of the medial epicondyle on flexion of the elbow (Fig. 12). Sonography can also differentiate ulnar nerve dislocation from other causes of medial elbow pain and ulnar nerve neuropathy, such as cubital tunnel syndrome and snapping triceps syndrome [8].

Muscle Changes Resulting from Nerve Pathology

Denervating neuromuscular disorders typically result in soft-tissue and muscle atrophy; this is associated with loss of muscle bulk and fatty infiltration. Causes include acute brachial neuritis and quadrilateral space syndrome. Pseudohypertrophy represents a combination of true muscle hypertrophy and an increase in intramuscular connective tissue and fat. Pseudohypertrophy frequently occurs in the calf muscles, and this phenomenon is seen in some dystrophic muscle conditions, hemihypertrophy syndromes, and chronic neuropathies. True muscle hypertrophy results from a pure increase in muscle bulk, without fatty infiltration. This is a paradoxical response to nerve injury and, although rare, it is associated with chronic nerve irritation [9] (Figs. 13–15).

Acknowledgment

We thank Barbara Taylor, Radiology Librarian, Royal Perth Hospital, for her assistance in manuscript preparation.

References

1. Fornage BD. Peripheral nerves of the extremities: imaging with ultrasound. *Radiology* 1988;167: 179–182
2. Martinoli C, Bianchi S, Derchi LE. Tendon and nerve sonography. *Radiol Clin North Am* 1999; 37:691–711
3. Murphey MD, Smith WS, Smith SE, Kransdorf MJ, Temple HT. Imaging of musculoskeletal neurogenic tumours: radiologic–pathologic correlation. *RadioGraphics* 1999;19:1253–1280
4. Martinoli C, Bianchi S, Gandolfo N. US of nerve entrapments in osteofibrous tunnels of the upper and lower limbs. *RadioGraphics* 2000;20:S199–S217
5. Zanetti M, Strehle JK, Zollinger H, Hodler J. Morton neuroma and fluid in the intermetatarsal bursae on MR images of 70 asymptomatic volunteers. *Radiology* 1997;203:516–520
6. Heilbrun ME, Tsuruda JS, Townsend JJ, Heilbrun MP. Intraneural perineurioma of the common peroneal nerve: case report and review of the literature. *J Neurosurg* 2001;94:811–815
7. Duncan I, Sullivan P, Lomas F. Sonography in the diagnosis of carpal tunnel syndrome. *AJR* 1999;173:681–684
8. Jacobson JA, Jebson PJL, Jeffers AW, Fessell DP, Hayes CW. Ulnar nerve dislocation and snapping triceps syndrome: diagnosis with dynamic sonography—report of three cases. *Radiology* 2001; 220:601–605
9. Reimers CD, Schlotter B, Eicke BM, Witt TN. Calf enlargement in neuromuscular diseases: a quantitative ultrasound study in 350 patients and review of the literature. *J Neurol Sci* 1996;143:46–56